Treatment of infra-inguinal bypass wound complications—a plastic surgeon's perspective

Kenneth Moquin, MD, MS

Plastic, Hand, and General Surgery
Senior Staff Surgeon
Henry Ford Health System
Detroit, Michigan

Disclosures

- Wound Care Speaker
  - Smith and Nephew
- Consultant
  - Cardinal Health

Concepts to Maximize Success When Treating Groin Wounds

- Debride non-viable tissue
- Clear gross infection (<100,000 cfu/mL)
- Irrigate (high vs low vs gravity flow)
- Wound Care vs Tissue Coverage
  - Exposed Critical Structures (bone, tendon, nerve, graft)
  - Tissue Coverage—Staged?
  - Wound Care—Short or Long Term?

Excisional Wound Debridement

Wound edges

Critical Structures

Graft—leave in situ vs replace vs divert

Excisional Wound Debridement

Scalpel

Currette

Serrated Scissors (black-handle)

Metal Ruler

High Powered Water Jet

Clear Gross Infection

How do you assess if a wound is infected?

smell, appearance, lab test (Qualitative vs Quantitative)

Clear Gross Infection

Qualitative

- Foul odor, sweet odor (*Pseudomonas*)
- Erythema, skin breakdown, ischemic tissue, exudate

Quantitative

- Swab culture—no role in 2017 ???
- Tissue biopsy
  - Quantitative Culture (CFU/mL)—at least 2 mg sample
    - 100,000 is threshold
  - Nucleic acid/Protein Mapping (e.g. 16S rRNA PCR)

Emerging Concept of Microbiome

Diagnosing Infection--Evidence

Nucleic acid/Protein Mapping

Application of quantitative real-time PCR for rapid identification of *Bacteroides fragilis* group and related organisms in human wound samples.

Tong J *et al*.

Anaerobe. 2011 Apr;17(2):64-8.

Designed specific primers and probes based on 16S rRNA gene sequences of *Bacteroides* species. Target bacteria were detected in samples 8% of time by culture and 33% of time by QRT-PCR

Diagnosing Infection—Evidence Against Swab

Nucleic acid/Protein Mapping

Diagnostic performance of swab PCR as an alternative to tissue culture methods for diagnosing infections associated with fracture fixation devices.

Omar M *et al.*
Injury. 2016 Jul;47(7):1421-6.

In 62 consecutive patients with implant-related infection, Tissue Culture (TC) and Swab PCR (S-PCR) tests were examined in subjects with known infections. TC detected infections in 47 cases vs S-PCR in 35 cases.

It appears that the method obtaining specimens plays an important role in diagnosing infection, even when employing molecular methods.

Wound Irrigation

High Pressure vs Low Pressure vs Gravity

(pulse evac vs asepto syringe vs cysto tubing)

Fluid of Choice

(saline vs anti-microbial)

Wound Irrigation--Evidence

Comparison of a low-pressure and a high-pressure pulsatile lavage during debridement for orthopaedic implant infection.

Munoz-Mahamud E *et al.*

Arch Orthop Trauma Surg. 2011 Sep;131(9):1233-8

Randomized prospective study of patients requiring open debridement for orthopaedic implant infection (HPP group N=42 LP group N=37)

High-pressure pulsatile lavage and low-pressure lavage had similar success rates ($p = 0.56$ trend towards better success with low-pressure)

Wound Irrigation

Can we do better than episodic irrigation??

And can we combine the benefits of Negative Pressure Wound Therapy (NPWT) with irrigation?

Wound Care—NPWT Definition

The controlled application of sub-atmospheric pressure to the local wound environment using a sealed dressing connected to a pump.

NPWT--History

- Earliest precursor seen during Roman era
  - “sucking healers”—persons provided direct contact suction by mouth for deep or poisonous wounds
  - “cupping glasses” also developed to provide longer treatment duration

Painting by Pablo Amaringo

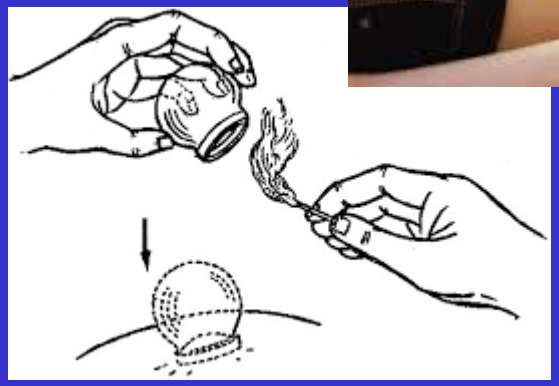

J Am Coll Clin Wound Spec. 2012 Sep; 4(3): 61–62. Published online 2013 Nov 28. doi: 10.1016

NPWT--History

- 18th century France saw "wound suckers" used to remove clots and foreign bodies from soldiers

Poison sucked from wound of Prince Edward
by his consort

J Am Coll Clin Wound Spec. 2012 Sep; 4(3): 61–62. Published online 2013 Nov 28. doi: 10.1016

NPWT--History

- 20th century
  - Swedish Plastic Surgeon published use of continuous irrigation with NPWT in 1970s
  - Russians began using NPWT with foam dressings in 1980s
  - Modern NPWT system introduced in 1990s by Dr. Louis Argenta

Dr. Pål Svedman

– Dr. Louis Argenta

Dr. Pål Svedman, M.D., Ph.D.

- Swedish Plastic & Reconstructive Surgeon/ Professor of Medicine at Lund University.
- First physician/inventor to propose combining Negative Pressure Wound Therapy (NPWT) with Simultaneous Irrigation.
- Began experiments with NPWT & irrigation in 1976
- Papers published in IRSC Medical Science, Scan J. Plastic Reconstructive Surgery, and the Lancet in the late 1970s.
- Key patent - 4,382,441, issued in 1983.
- First products put into clinical use in the early 1980's.

Dr. Pål Svedman, M.D., Ph.D.

"Two-Port Irrigation Dressing"

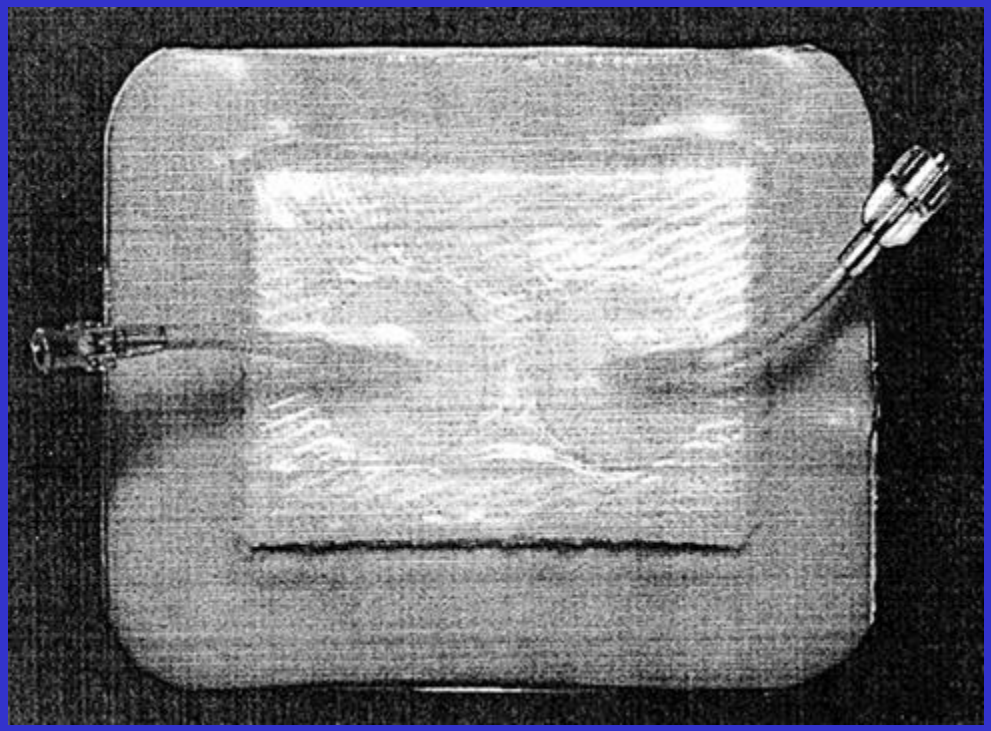

1985

How is Irrigation Solution Distributed Across the Wound Bed?

International Wound Journal ISSN 1742-4801
ORIGINAL ARTICLE

The fluid dynamics of simultaneous irrigation with negative pressure wound therapy

Kathryn E Davis[1], Kenneth J Moquin[2] & Lawrence A Lavery[1]

1 Department of Plastic Surgery, University of Texas Southwestern Medical Center, Dallas, TX, USA
2 Department of Plastic Surgery, Henry Ford Hospital, Detroit, MI USA
Int Wound J. 2016 Aug;13(4):469-74.

Correspondence to
KE Davis, PhD
Co-Director of Research, Department of
Plastic Surgery
University of Texas Southwestern Medical
Center
5323 Harry Hines Blvd F4.310A
Dallas, TX 75390-8560
USA
E-mail: Kathryn.davis@utsouthwestern.edu

Fluid Dynamics of Simultaneous Irrigation

OBJECTIVE: Demonstrate the Fluid Dynamics of Simultaneous Irrigation during NPWT

- 3-dimensional wound model created using clear ballistic gel
- Assess the distribution of fluid across the wound beds using simultaneous irrigation visualized in real time.
- Studied simultaneous irrigation fluid dynamics in simple and complex wound models.
- Visualized fluid displacement during continuous irrigation

Creating the Wound Molds

Wound models were constructed using clear synthetic ballistic gel (Clear Ballistics, Fort Smith, Arkansas).





Experimental Model

Experimental Methods

- Wounds (3) with varying characteristics (irregular wound topology, undermining, fissures, bridging, etc) were carved at varying areas, depths and volumes into the ballistic gel
- Wound models used for this study were packed with hydrophobic polyurethane foam
- To allow visualization of the irrigation solution, white polyurethane foam (as opposed to the standard black foam) was applied against the wound bed and filled with black PU foam in the center.
- Wounds were covered with drape and speed connects were placed on the dressing and connected to the NPWT device and irrigation solution.

3-Dimensional Wound Model



Bridged 3-Dimensional Wound

Simultaneous irrigation effectively distributes the irrigation solution throughout the wound bed of bridged wounds. (Stochastic Displacement)



Studying the impact of NPWT with and without simultaneous irrigation

Use animal wound model

Examine wound healing and biodurden

Preclinical Trial: "The Davis Bioburden Reduction Study"

OBJECTIVES

- To determine if the NPWT with and without Simultaneous Irrigation accelerates wound healing
- To determine if simultaneous irrigation with Saline or the antimicrobial, Prontosan, reduces wound bioburden.

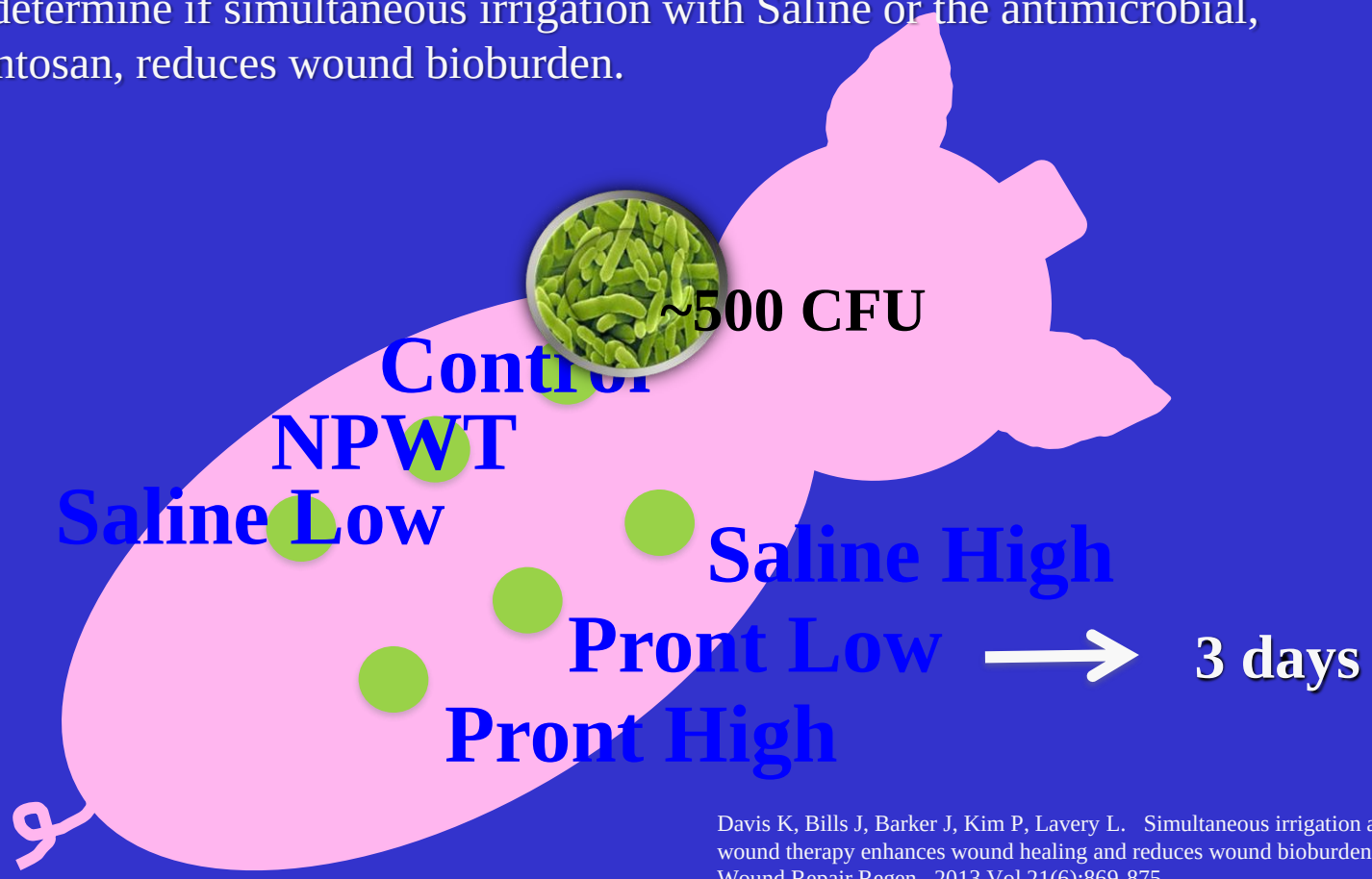

Davis K, Bills J, Barker J, Kim P, Lavery L. Simultaneous irrigation and negative pressure wound therapy enhances wound healing and reduces wound bioburden in a porcine model. Wound Repair Regen. 2013 Vol 21(6):869-875.

Wound Healing and Bioburden Study: Methods

EXPERIMENTAL DESIGN:

- 21 days of therapy
- Dressing changes 2x/week
- Monitored every 12 hours
  - Canister volume
  - Infusion bag volume
  - Patch integrity
  - Pump alarms etc.

STUDY ENDPOINTS:

- Wound Healing Rates
- Bacterial Analysis at each dressing change utilizing qPCR
  - Normal Saline vs Prontosan
  - Fast vs Slow Irrigation Rates

Davis K, Bills J, Barker J, Kim P, Lavery L. Simultaneous irrigation and negative pressure wound therapy enhances wound healing and reduces wound bioburden in a porcine model. Wound Repair Regen. 2013 Vol 21(6):869-875.

Results: Daily Infusion Volumes

(20 drops = 1 cc)

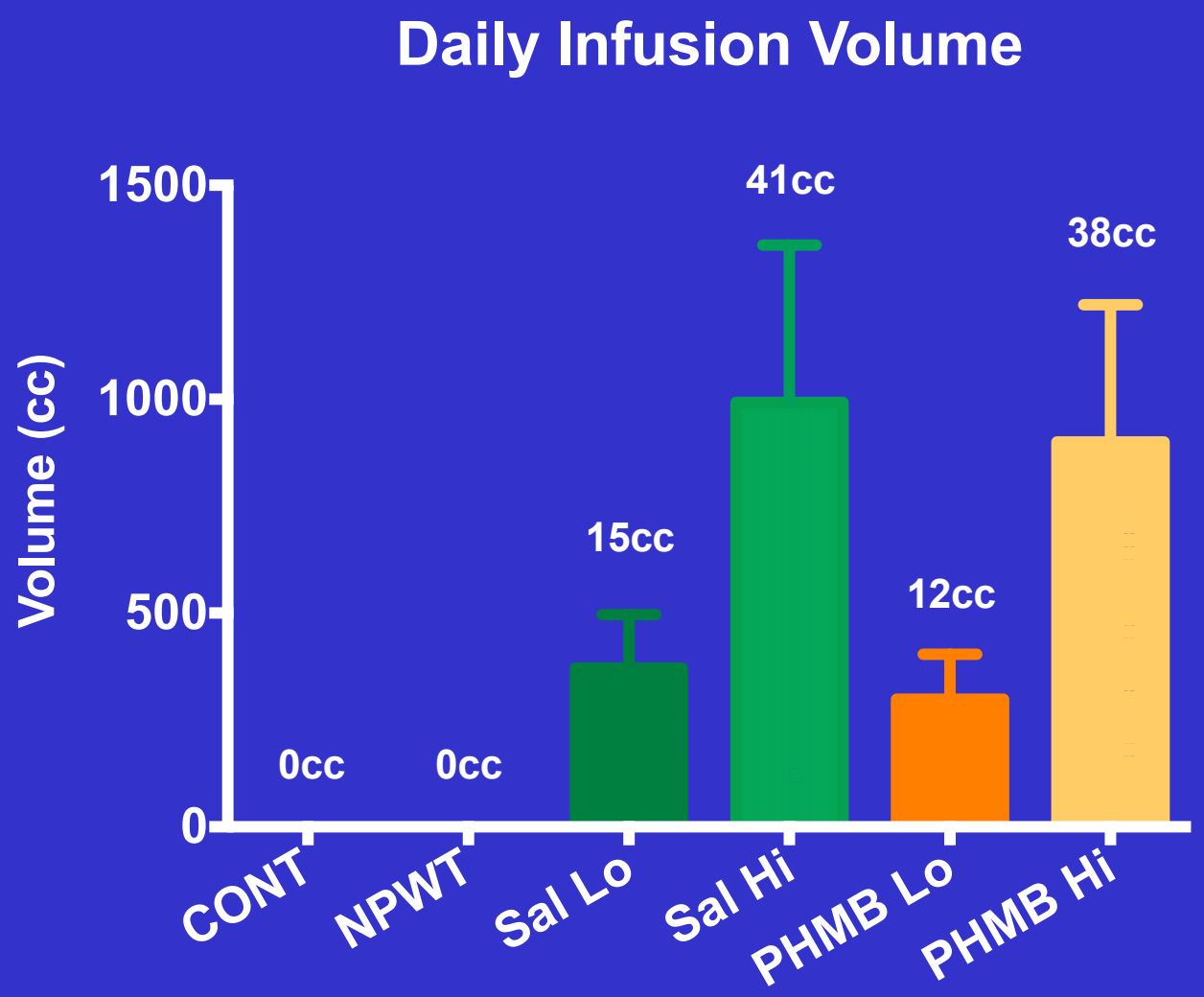

Low flow = 5-15cc/hr

High flow = 30-40cc/hr

Davis K, Bills J, Barker J, Kim P, Lavery L. Simultaneous irrigation and negative pressure wound therapy enhances wound healing and reduces wound bioburden in a porcine model. Wound Repair Regen. 2013 Vol 21(6):869-875.

NPWT With or Without Simultaneous Irrigation Reduces Wound Area

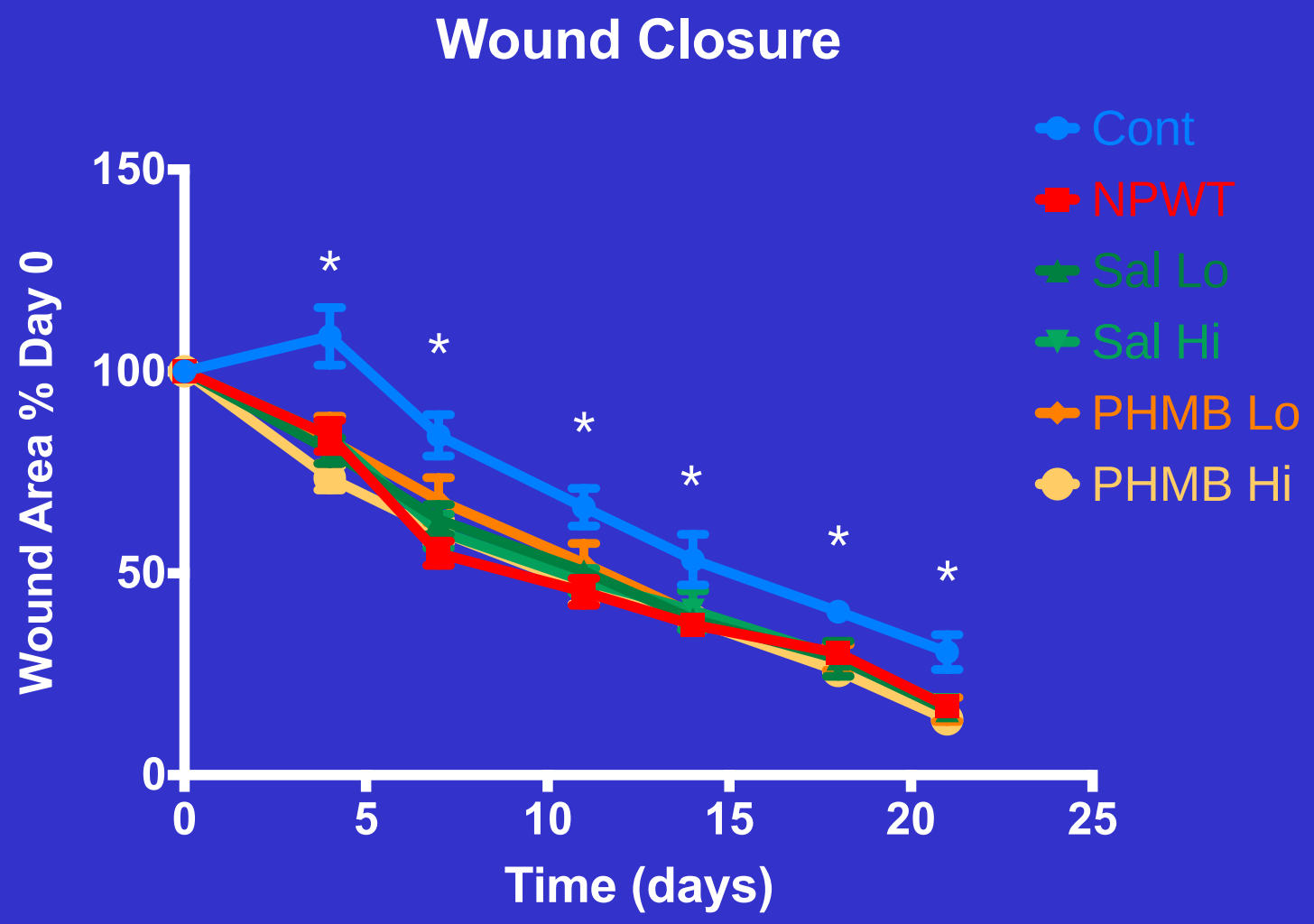

Davis K, Bills J, Barker J, Kim P, Lavery L. Simultaneous irrigation and negative pressure wound therapy enhances wound healing and reduces wound bioburden in a porcine model. Wound Repair Regen. 2013 Vol 21(6):869-875.

Simultaneous Irrigation with Both Saline and Prontosan Significantly Reduce Bacteria over NPWT alone or CTL

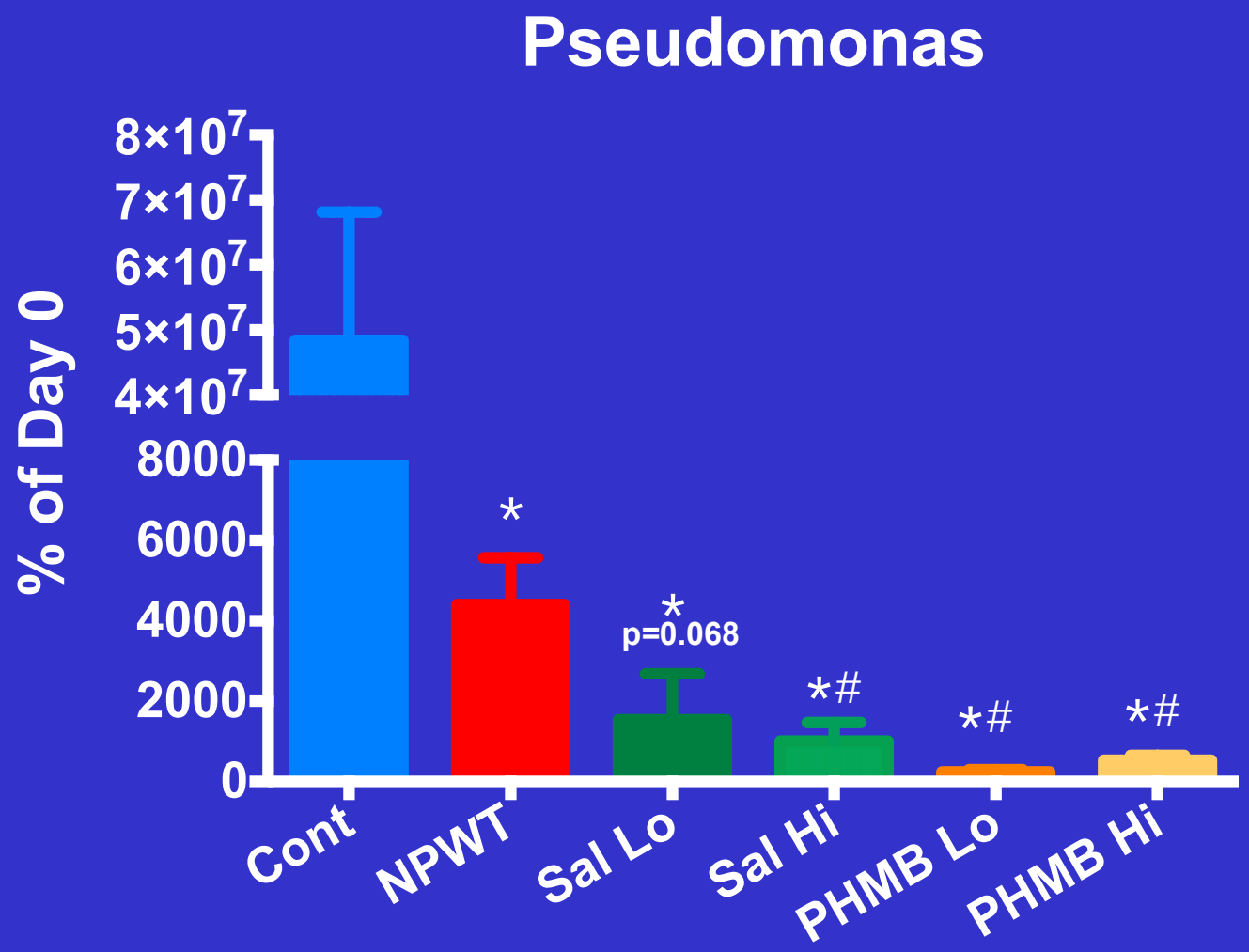

Davis K, Bills J, Barker J, Kim P, Lavery L. Simultaneous irrigation and negative pressure wound therapy enhances wound healing and reduces wound bioburden in a porcine model. Wound Repair Regen. 2013 Vol 21(6):869-875.

Conclusions

- In an acute wound healing model, both NPWT alone and NPWT with simultaneous irrigation reduce wound volume
- NPWT reduces bioburden (measured by qPCR) compared with control therapy
- NPWT with simultaneous irrigation, whether with saline or the antimicrobial, Prontosan, significantly reduces bioburden over NPWT and control dressings alone.
- Improvement in bioburden does not correlate with accelerated wound healing over NPWT alone in a porcine model
- The effects of irrigation therapy will likely be more correlated to wound healing in a clinical setting and with chronic wounds.

Use of standard NPWT may alter wound microbiome

Bacterial reduction and shift with NPWT after surgical debridements: a retrospective cohort study.

Jentzsch T *et al.*
Arch Orthop Trauma Surg. 2017 Jan;137(1):55-62.

After OR debridement, NPWT, antibiotic treatment, and primary and secondary consecutive microbiological samples were done from 115 patients with open wounds showing positive cultures.

Secondary samples showed significantly less bacterial growth (32 vs 89%, p<.001)– Gram-positive bacteria (56 vs 78%, p=.013), facultative anaerobes (64 vs 85%, p=.011) and Staph aureus (10 vs 46%, p=.002).

However, there were more Coagulase-negative *Staph* (44 vs 18%) and *Pseudomonas* species (31 vs 7%)

Most wounds closed within 11 days.

Groin Tissue Coverage

Historic options

- Sartorius muscle
  - segmental (Type IV) blood supply limits arc
- Rectus abdominis
  - requires patent deep inferior epigastric vessels
- TFL muscle
  - little muscle provided and donor site morbidity
- Omentum
  - abdominal laparotomy—inadequate volume/adhesions
- Rectus femoris
  - perceived donor site functional morbidity

Clinical Case

74 y/o male s/p resection of SCCA from left groin with radiation years ago who was treated for PVOD with a femoral endarterectomy and patch angioplasty 6 months prior. His groin wound would not heal and he had a herald bleed and was transferred for escalation of care.

He had surgery for a femoral pseudoaneurysm with resection and external iliac to profunda bypass with jump graft to superficial femoral using cryopreserved femoral artery. A wound VAC was placed. 10 days later a pedicled rectus femoris muscle flap was used to fill the wound followed by a VAC. Wound care was then instituted outpatient for 6 weeks after which a STSG was done using a VAC bolster.

Rectus Femoris Clinical Case

Rectus Femoris Clinical Case

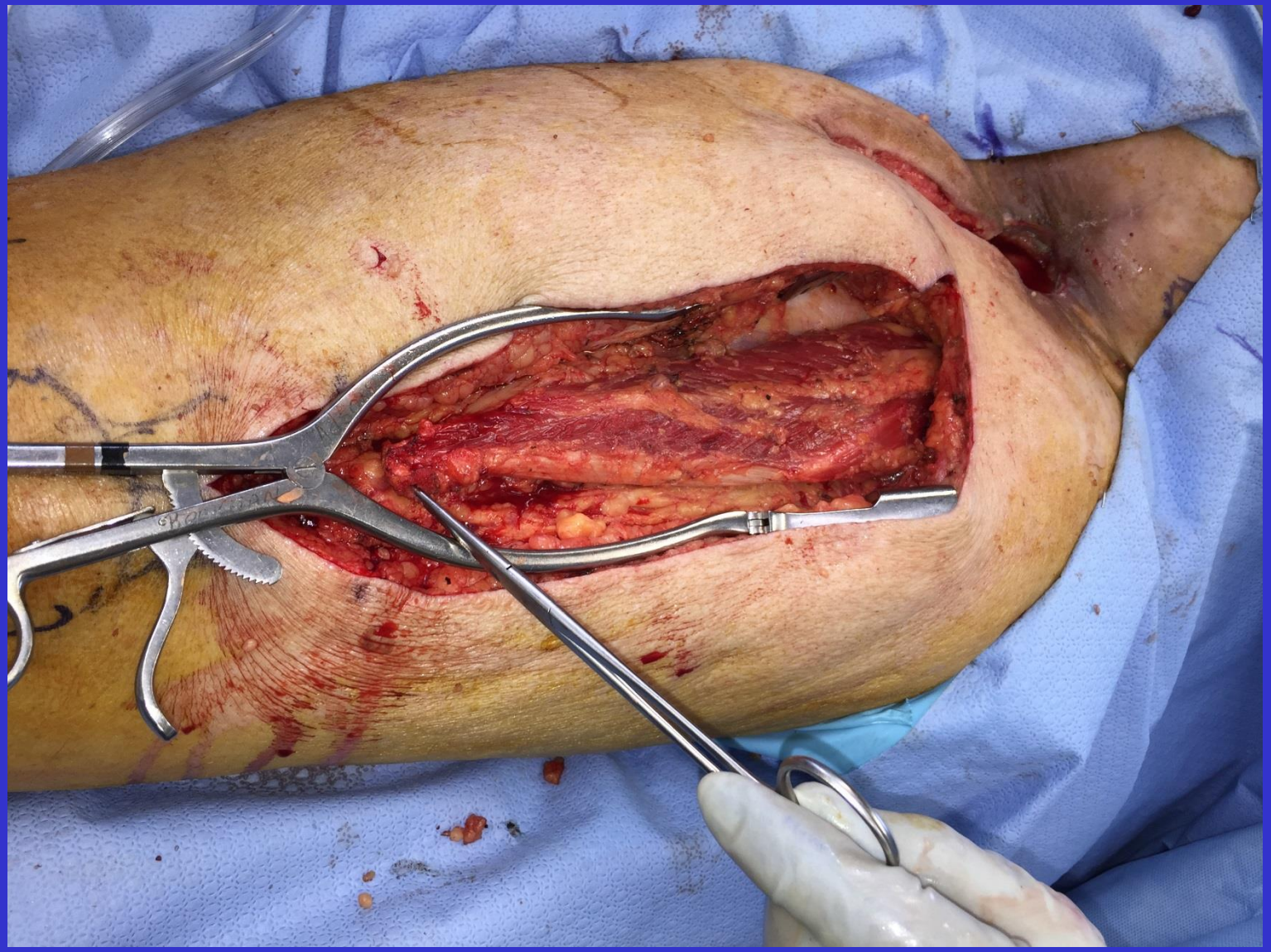

Rectus Femoris Clinical Case

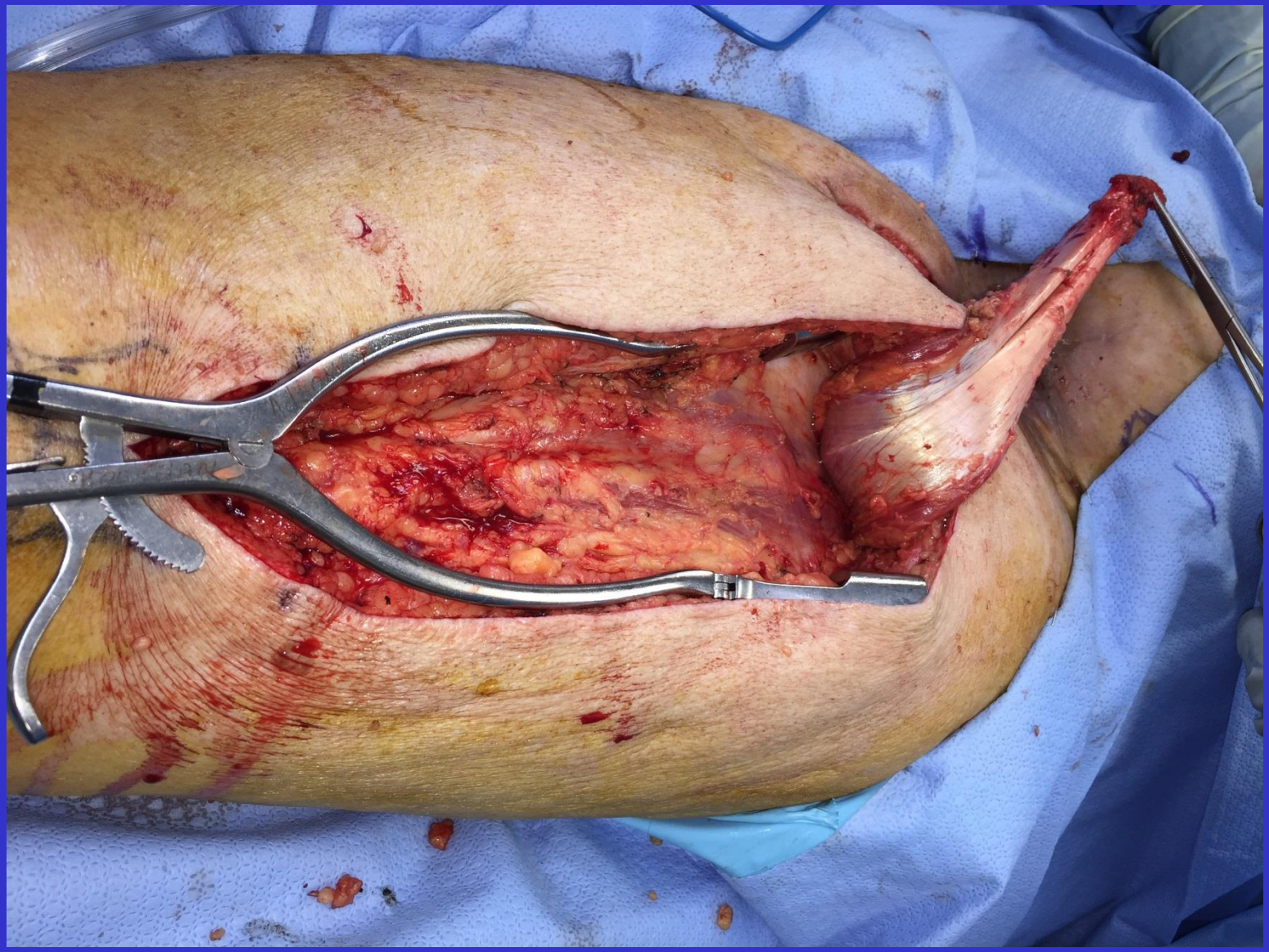

Rectus Femoris Clinical Case

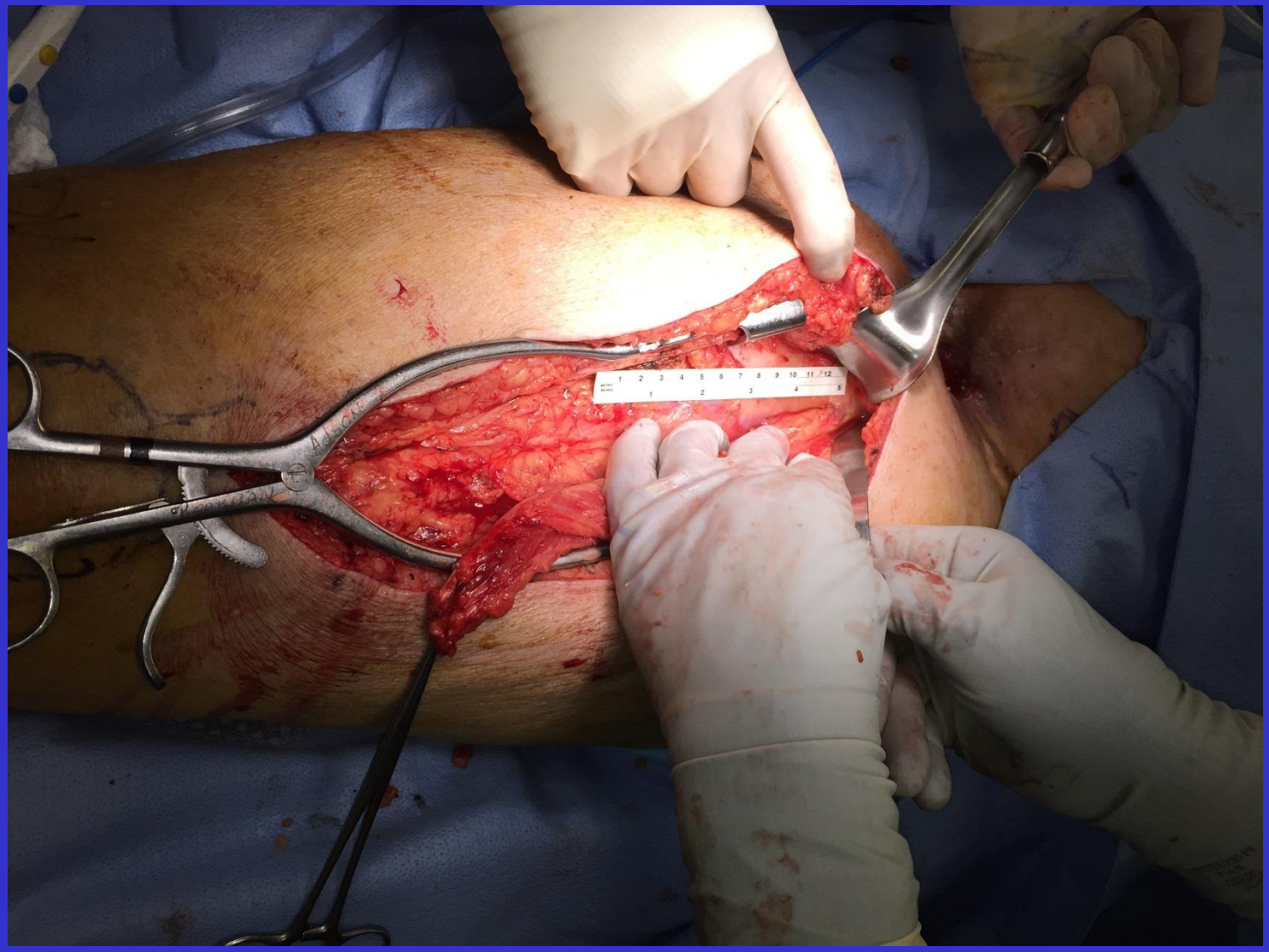

Rectus Femoris Clinical Case

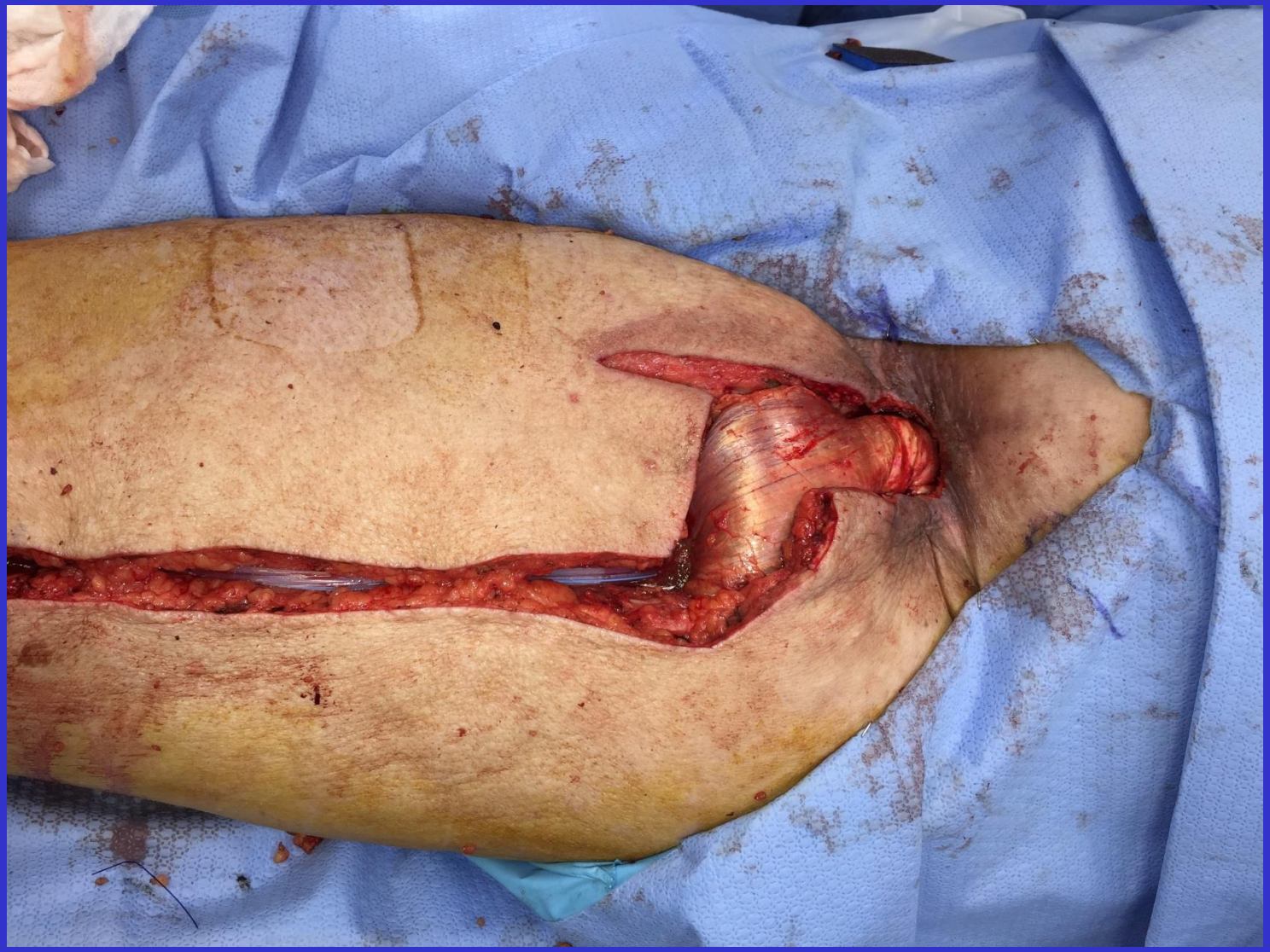

Rectus Femoris Clinical Case

Rectus Femoris Clinical Case

Rectus Femoris Clinical Case

Rectus Femoris Flap

-The most anterior muscle of the Quadriceps group

-Origin: ASIS and upper acetabulum

-Insertion: Patellar tendon (with vastus lateralis, medialis, and intermedius)

-Blood Supply: dominant—descending branch of lateral femoral circumflex off profunda femoral artery. Minor—small branches from superficial femoral artery (Mathes-Nahai Type II flap)

-Nerve: branch of femoral nerve

-Loss affects the terminal 10 degrees of knee extension

--avoided by plicating the Vastus lateralis to the vastus medialis above the patella with permanent suture (Prolene)

-Line from the ASIS to mid-patella, medial to vastus lateralis and lateral to Sartorius

-Can be left attached superiorly or freed up on only the pedicle

Evidence—Rectus Femoris

Donor-site morbidity of the pedicled rectus femoris muscle flap.

Daigeler A *et al*.
Plast Reconstr Surg. 2005 Mar;115(3):786-92.

14 Patients were followed for 3-56 months postoperatively. Questionnaire was used to survey walking, function, aesthetics, sensibility. 10 patients had testing using the twitch interpolation technique—results showed maximal voluntary contraction and true muscular capacity values reduced when compared with opposite leg (21.8% and 18%). ROM of hip and knee was not affected. Patient satisfaction with both functional and aesthetic result was high. Despite donor-site morbidity, patients are well compensated.

Evidence—Rectus Femoris

Rectus femoris muscle flap donor-site morbidity.

Gardetto A *et al*.
JPRAS 2005 Mar;58(2):175-82.

Examined affected leg compared to contralateral leg using strength tests (Leg press/Isometric/Force Platform). They found no significant limitation in the strength of the donor leg. They recommend intra-operative linking of the vastus lateralis with the vastus medialis muscle as well as postoperative rehabilitation.

Evidence—Rectus Femoris

Management of complex groin wounds: preferred use of the rectus femoris muscle flap.

Alkon JD *et al.*

Plast Reconstr Surg. 2005 Mar;115(3):776-83; discussion 784-5.

Examined hospital and outpatient records for 33 patients (age 25-88 years) for groin wounds due to intrainguinal revascularization (81%--76% had prosthetic material) and remainder occurred after cannulation procedure. No flap losses. Total 37 flaps. 94% healed—(70% primarily, 25% delayed healing), Re-operation for flap readvancement was done in 1 patient and in 3 patients for graft removal. No donor site wound complications. 89% of the groin wounds were culture positive. The rectus femoris flap is effective and reliable for groin reconstruction and is the flap of choice.

Evidence—Rectus Femoris

A Cost-Utility Analysis Comparing the Sartorius versus the Rectus Femoris Flap in the treatment of the Infected Vascular Groin Graft Wound.

Chatterjee A *et al*.

Plast Reconstr Surg. 2015 Jun;135(6):1707-14.

Cost-utility methodology: literature review of flap outcomes, utility scores for complications, accruing costs using DRG and CPT codes for interventions and developing a decision tree. Sensitivity analyses were performed. Szilagyi III (deep alloplastic graft infection) and Samson III (graft, not anastomosis) and IV (anastomosis) grades of infected groin grafts were included.

26 studies were used pooling 296 patients (234 Sartorius and 62 rectus flaps). Rectus femoris flap was more effective by an additional 0.30 quality- adjusted life-years. The Sartorius flap cost an additional $2241.88 with major complication rate of 13.68 vs 8.6% for rectus flap. The rectus femoris flap is a cost-effective option compared with the Sartorius flap for infected vascular graft groin wounds.

Evidence--NPWT Cost vs Sartorius

Cost-Utility Analysis: Sartorius Flap versus Negative Pressure Therapy for Infected Vascular Groin Graft Management.

Chatterjee A *et al.*

Plast Reconstr Surg Glob Open. 2015 Dec 9;3(11):e566.

Sartorius flap and NPWT have been described in managing infected vascular groin grafts with varying success.

METHODS: Literature review compiling outcomes for Sartorius flap and NPWT interventions done from peer-reviewed journals in Medline and EMBASE. Utility scores were derived and used to estimate quality-adjusted life years (QALYs). CPT and DRG codes were used to assess the costs for graft salvage with associated complications.

RESULTS: 32 studies were used pooling 384 patients (234 Sartorius flaps and 150 NPWT).

NPWT had better clinical outcomes (86.7% success rate, 0.9% minor complication rate, 13.3% major complication rate) than Sartorius flap (81.6% success rate, 8.0% minor complication rate, 18.4% major complication rate). NPWT was less costly ($12,366 vs $23,516) and slightly more effective (12.06 QALY vs 12.05 QALY) compared with Sartorius flap.

CONCLUSION: Use of NPWT, along with debridement and antibiotic treatment for managing infected vascular groin graft wounds was determined to be a more cost-effective option compared with Sartorius flaps.

Using NPWT Over Closed Incisions

Why are you not doing it ???

Concept differs from open wound NPWT usage where suction removes edema/contaminated fluids, mechanically reduces wound size, optimizes formation of granulation tissue (micro and macrovascular tissue strain).

Incisional NPWT involves **compression**. Compression of the zone of injury (NOT JUST THE INCISION) optimizes healing by reducing seroma formation, and peri-wound interstitial edema thereby optimizing wound perfusion.

Integrating NPWT into all phases of wound care

-After initial debridement—use NPWT as sterile dressing, to reduce edema, aid with mechanical contraction and allow physiology optimization. Consider incorporating continuous irrigation with fluid of choice (e.g. saline, 0.25% acetic acid, ¼ or ½ strength Dakin's solution) based upon wound hostility. Can apply sponge material (white foam) directly over skin surrounding wound to distribute force w/o skin trauma.

-if graft exposed, use white foam (small pore size and soft material)

-After flap with primary closure (or after elective primary closure), consider incisional NPWT to decrease risk of SSC. Remember unlike open wound NPWT usage, incisional NPWT efficacy involves compression and not suction so consider zone of tissue injury.

-After skin grafting as a bolster. Can link to donor site and incorporate irrigation to optimize patient comfort and epithelialization. Okay to irrigate over fresh skin grafts.

Opportunity to Improve

Underlying reasons associated with hospital readmission following surgery in the United States

Merkow R *et al.*

JAMA. 2015 Feb 3;313(5);483-5.

Sample - 346 ACS-NSQIP enrolled hospitals January – December 2012

Examined readmission rates for all surgical procedures n = 498,875

Unplanned re-admission rate was 5.7%

Readmissions after surgery related to new post discharge complications

Most common reason for unplanned readmission was Surgical Site Infection (SSI) at 19.5%

iNPWT Evidence

Negative pressure wound therapy to prevent seromas and treat surgical incisions after total hip arthroplasty

Pachowsky M *et al.*

Int Orthop. 2012 Apr;36(4):719-22.

Prospective randomized trial involving 19 patients randomized to either a standard post-op dressing or iNPWT after total hip arthroplasty. Ultrasound was used to examine the peri-wound at day 5 and 10.

Total hip arthroplasty: 9 patients with incisional NPWT for 5 days v 10 patients with standard dressings. Used ultrasound to visualize a reduction in the development of seromas ($p= 0.021$).

Guidelines for the Use of Incisional NPWT

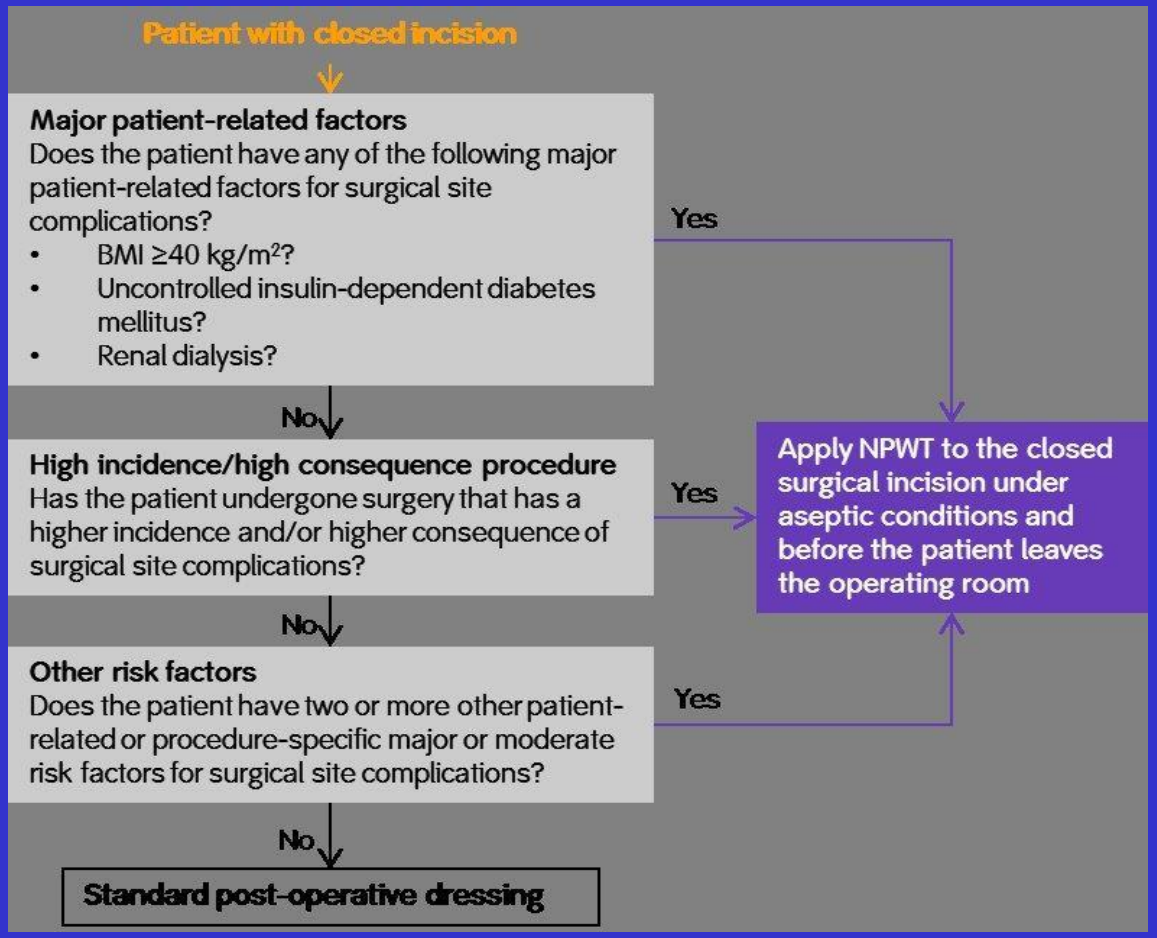

World Union of Wound Healing Societies (WUWHS) Consensus Document. Closed surgical incision management: Understanding the role of NPWT. Wounds International, 2016. Figure 2

Incisional NPWT--Evidence

Randomized clinical trial of negative pressure wound therapy for high-risk groin wounds in lower extremity revascularization.

Lee K *et al.*

J Vasc Surg. 2017 Aug 30. pii: S0741-5214(17)31771-8.

METHODS:

Single center, randomized, controlled trial involving 102 patients classified as high risk for SSI due to previous femoral artery exposure (29%), BMI >30kg/m2 (39%), or the presence of ischemic tissue loss (32%). All wounds were closed primarily and patients randomized to either iNPWT or standard dressing. Primary outcome: post-op 30-day groin wound SSI. Secondary outcomes: 90-day SSI, hospital LOS, readmissions/reoperations for SSI, and mortality.

RESULTS:

30-day SSI was 11% in NPWT group and 19% in standard dressing group (p=0.24). There was a statistically shorter mean hospital LOS in NPWT group (6.4 days) vs the standard dressing group (8.9 days; p=0.01). No difference in readmission or reoperation for SSI, or mortality.

CONCLUSION:

A nonsignificant lower rate of groin SSI in high risk revascularization patients with NPWT compared with standard dressing.* NPWT group did show a significantly shorter hospital LOS compared with standard dressing group.

*Study was underpowered to detect a difference between the 2 groups because of a lower than expected infection rate.

NPWT in Vascular Surgery--Evidence

Negative-pressure wound therapy for prevention and treatment of surgical-site infections after vascular surgery.

Acosta S *et al.*
Br J Surg. 2017 Jan;104(2):e75-e84.

A review to outline evidence for NPWT on open and closed wounds.

METHODS:

A PubMed, EMBASE and Cochrane Library search from 2007 to 2016.

RESULTS:

-NPWT in open groin wounds—shorter duration of wound healing by 47 days and more cost-effective than alginate dressings in one RCT

-One retrospective comparative study showed a significant reduction in surgical-site infection using incisional NPWT (6%) compared with standard wound care (30%)

CONCLUSION:

NPWT has central role in open and infected wounds after vascular surgery with results of iNPWT being promising.

Thank You